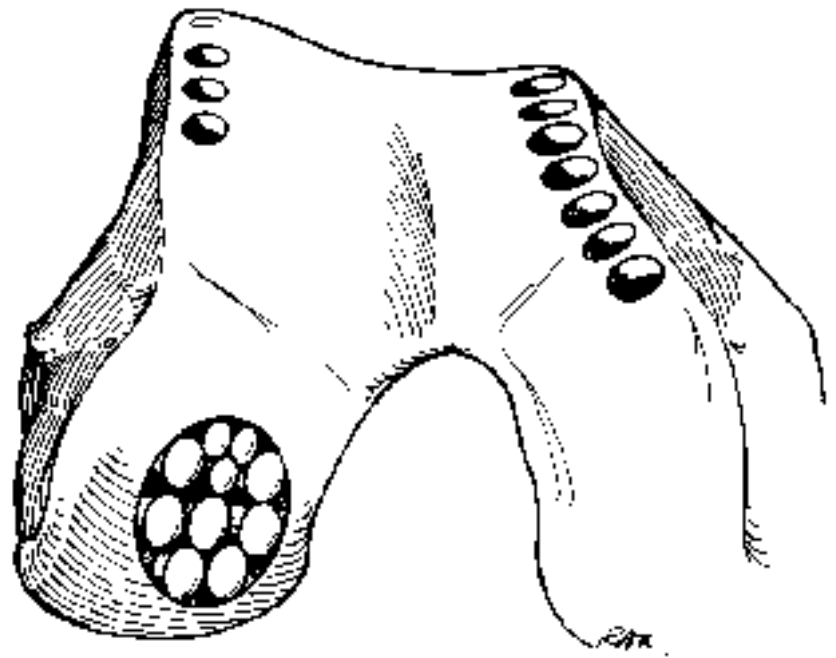


Osteochondral grafting using the Smith & Nephew MOSAICPLASTY[®] System



Osteochondral grafting using the Smith & Nephew MOSAICPLASTY[®] System

As described by

Prof. László Hangody, M.D., Ph.D., D.Sc.
Uzsoki Hospital, Orthopaedic and Trauma Department,
Budapest, Hungary

Anthony Miniaci, M.D., FRCS
Toronto Western Hospital, Toronto, Ontario, Canada

Gary A. Z. Kish, M.D.
Saint George Medical Center, Portsmouth, NH, USA

Localized articular cartilage defects in weight-bearing joints are common, yet difficult to treat. MOSAICPLASTY grafting represents a method of autogenous osteochondral transplantation for the treatment of focal cartilaginous defects secondary to biomechanical chondropathy, traumatic chondral lesions and osteochondritis dissecans of the knee and ankle. The success rate is higher for patients under age 50 due to biochemical changes in the synovial fluid that occur after age 50. (See Bibliography for references.)

This procedure can generally be performed arthroscopically for lesions of the femoral condyles when the defect is close to the intercondylar notch and does not exceed 2 cm in diameter, and does not need more than 4–6 grafts. Larger defects may be treated as experience is gained with the technique.

Overview

The MOSAICPLASTY technique involves obtaining small osteochondral cylindrical grafts from the less weight-bearing periphery of the femur at the patellofemoral joint, and transporting them to the prepared defect site. With a combination of 2.7 mm, 3.5 mm, 4.5 mm, 6.5 mm, and 8.5 mm grafts, the site is filled with 70–90% transplanted hyaline cartilage. Fibrocartilage “grouting” growing upward from the prepared cancellous bed will complete the MOSAICPLASTY graft.

Postoperatively, the patient should be kept non-weight-bearing with no partial loading for 2–6 weeks and encouraged to reestablish full ROM. This time period and activity level will allow:

- The grafts to bond to surrounding bone and cartilage;

- The surface to remain congruent without subsidence of the press-fit transplanted osteochondral graft.

Note: Chisels, drill guides, and trephines must be sharp. Replace drill guides and trephines when damaged or dull. For consistent results, use disposable chisels for each procedure. The cutting edge cannot be resharpened without compromising the self-centering geometry of the original tip.

IMPORTANT: Placing the grafts perpendicular to the surface, at the level of the original articular surface, is paramount to the success of the operation.

Patient Consent

For the most part, cartilaginous lesions are only defined at arthroscopy. If the preoperative differential diagnosis includes such a lesion, the patient should be advised of the possibility of a MOSAICPLASTY graft. The patient should be prepared for an open procedure if the site is inaccessible due to location posterior or there is inability to flex the knee sufficiently. This procedure can lead to an overnight stay and altered weight-bearing status for several weeks.

Contraindications

Infectious or tumor defects.

Generalized arthritis, rheumatoid and/or degenerative in type.

Those patients under the age of 50 with early unicompartment arthritis where the donor site cartilage is thin and the cartilage surrounding the defect is of poor quality.

In malaligned or unstable joints (varus or valgus, patellar-subluxation), restoration or joint mechanics needs to be addressed separately, or at the time of, the MOSAICPLASTY procedure. Patellar realignment, ACL, PCL, meniscal repair, and osteotomies can be done concurrently.

Operative Preparation

1. Holding area IV antibiotics.
2. Anesthesia: General or regional, with tourniquet control.
3. Patient is positioned supine with knee capable of 120° flexion. Contralateral extremity is placed in a stirrup.
4. Standard EUA and arthroscopic survey technique.

Choosing a Procedure

An open procedure may be chosen when first performing the technique or when an arthroscopic approach is not practical due to the size or location of the lesion. With the exception of this portal location, this technique applies to both open and arthroscopic procedures.

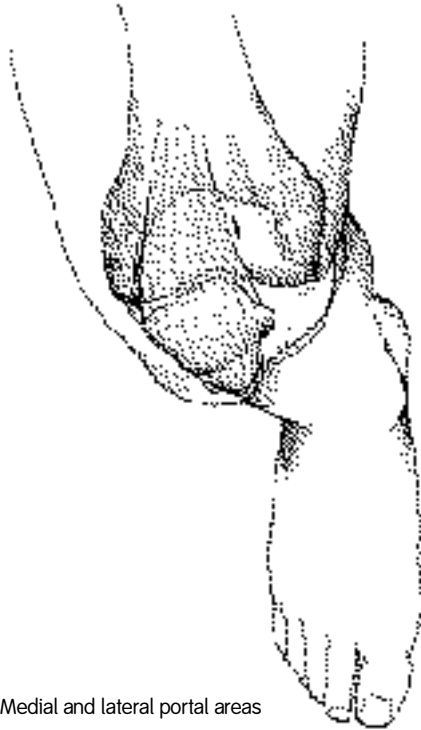


Figure 1. Medial and lateral portal areas

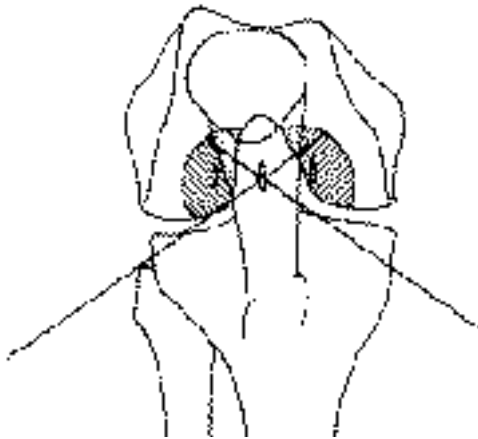

Figure 2. Range of working portal instruments direction.

Surgical Technique

Portal Selection

Perpendicular access to the lesion is critical to proper insertion of the grafts. Care must be exercised in making the viewing and working portals. For most femoral condylar lesions, central anterior medial and central anterior lateral portals will allow correct access. Initially, a 1.2 mm K-wire or 18 gauge spinal needle can be used to locate the portal sites (Figure 1). It should be noted that these portals tend to be more central than the standard portals due to the inward curve of the condyles (Figure 2).

For osteochondritis dissecans on the medial femoral condyle the approach needs to be from the lateral side. A standard lateral portal is sometimes too oblique. Therefore, use the central patellar tendon portal which gives good access to the inner positions of both the medial femoral condyle and the lateral femoral condyle.

If an arthroscopic approach will not be practical, it may be necessary to create a medial or lateral anterior sagittal incision, or an oblique incision.

Defect Preparation

1. With the use of a full radius resector or curette and a knife blade, the edges of the defect are brought back to good hyaline cartilage at a right angle (Figure 3).
2. Abrade the base of the lesion to viable subchondral bone with an abrader or half-round rasp (Figure 4).
3. Use a drill guide to determine the number of grafts needed (Figure 5).
4. A dilator may be used to measure the depth of the defect.

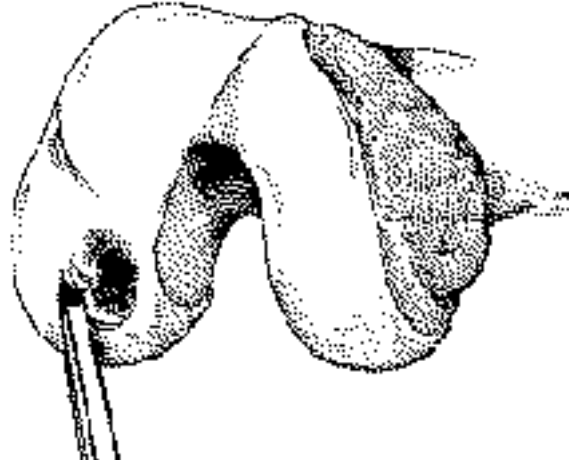


Figure 3

Procurement of Osteochondral Grafts

The grafts can be obtained either arthroscopically or through a mini-arthrotomy (1.5–2.0 cm). If the grafts are to be taken arthroscopically, certain points are emphasized. The preferred sites are the medial femoral condyle periphery of the patellofemoral joint or the lateral femoral condyle above the sulcus terminalis above the line of the notch. If additional grafts are needed, up to three grafts may be obtained from the standard portals. If more grafts are needed or if you want to go superiorly, superomedial or superolateral portals may be necessary. Additional grafts can be harvested by flexing or extending the knee.

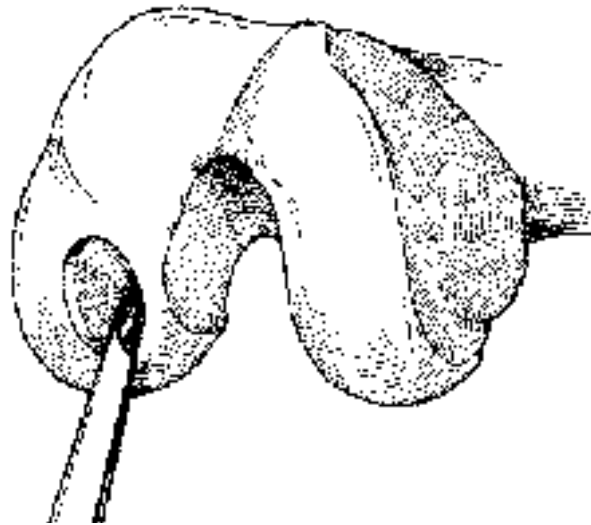


Figure 4

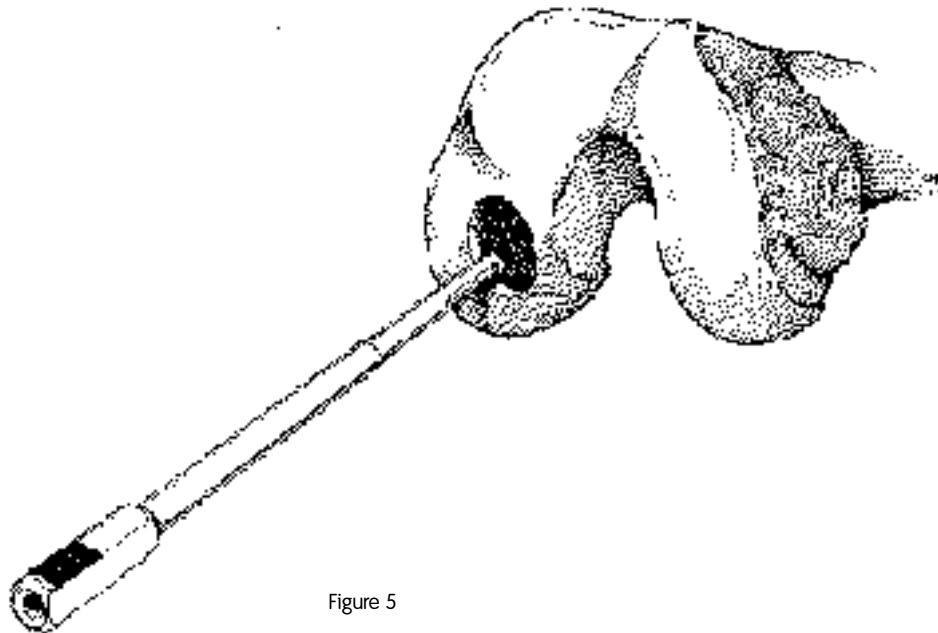


Figure 5

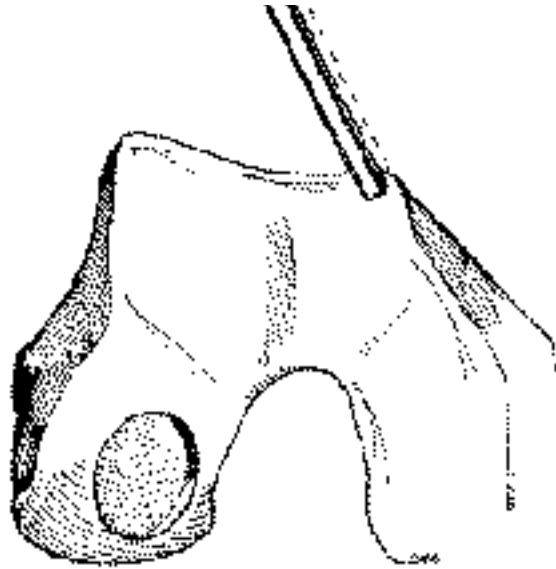


Figure 6

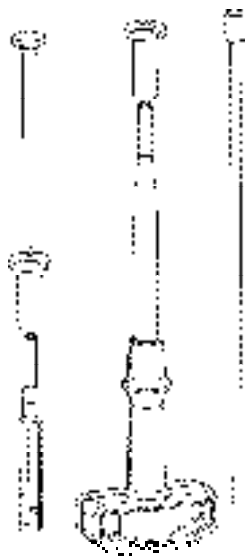


Figure 7a

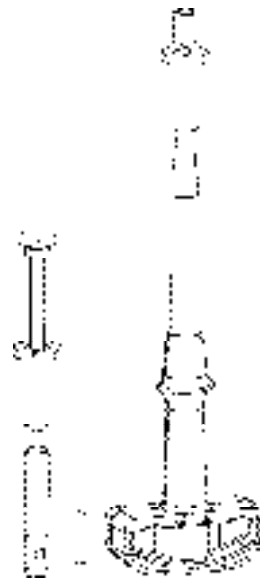


Figure 7b

The best view for harvesting grafts from the superior portals is obtained by introducing the scope through the inferior ipsilateral portal. The lateral femoral condyle periphery through a small arthrotomy (15–20 mm) is another option for grafts.

1. Use a spinal needle or a K-wire to locate the donor site, and then make the portal.
2. Introduce the proper-sized tube chisel with the harvesting tamp.
3. Once the site has been clearly identified, locate the chisel perpendicular to the articular surface (Figure 6) and drive it by hammer to the appropriate depth, usually 15 mm. Generally, the length of the graft should be at least two times its diameter. It is important to hold the chisel firmly to avoid it shifting at the cartilage/bone interface, producing a crooked graft.

Note: By flexing the knee, lower sites can be obtained. The lower limit is the top of the intercondylar notch.

Insert the 4.5 mm harvesting tamp into the crosshole in the tubular chisel and use it as a lever. Alternatively, single-use chisels can be used.

4. Toggle (do NOT rotate) the chisel, causing the graft to break free at the chisel tip.
5. Eject the grafts from the chisel by sliding the appropriate-sized chisel guard over the cutting end (Figure 7a).
6. Using the tamp, push the graft out (Figure 7b) onto gauze in a saline-wetted basin.
7. Measure the harvested grafts to determine the depth necessary to drill the recipient holes in the defect site.

Spacing the grafts to avoid confluence at depth (approximately 3 mm) will avoid any weakening of the condyle. The donor site holes will eventually fill with cancellous bone and fibrocartilage. Care should be taken when harvesting 6.5 mm and 8.5 mm grafts to avoid creating patellar tracking problems or weakening the condyle.

Insertion of Osteochondral Grafts

Drill/Dilate/Deliver (3D Grafting)

Drill

1. With the knee flexed and good distention established, reintroduce the drill guide using the dilator as an obturator. Place it in the defect perpendicular to the surface. By rotating the arthroscope, the drill guide and the perpendicularity of the laser mark can be seen from different angles, ensuring proper orientation. Then tap it into the subchondral bone.
2. Insert an appropriately-sized drill bit and drill to the desired depth (Figure 8). Generally, a recipient hole a few millimeters deeper than the length of the graft is desirable to minimize high intraosseal pressure. Inflow is now reduced to minimize leakage.
3. Remove the drill bit.

Dilate

1. Insert the dilator into the drill guide. Tap to the desired depth.
2. While firmly holding the drill guide, insert the 2.7 mm harvesting tamp into the dilator and use it as a lever to remove the dilator from the hole (Figure 9).

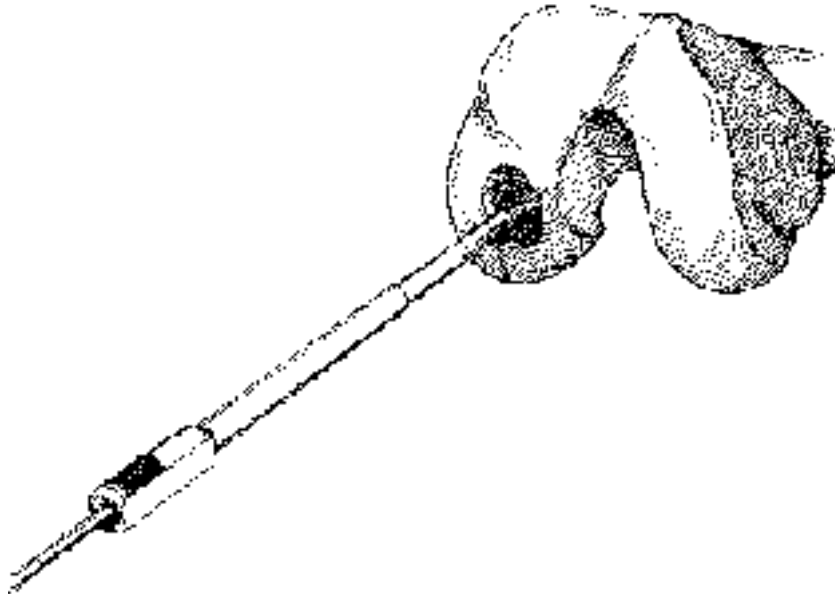


Figure 8. A 4.5 mm drill guide secured in defect with drill bit through the guide.

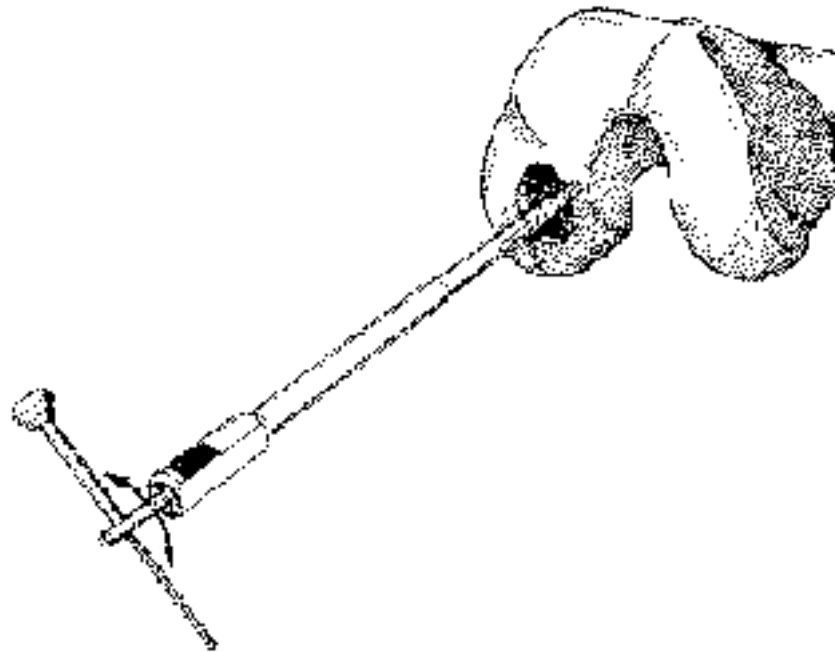


Figure 9. The dilator is removed using the 2.7 mm harvesting tamp.

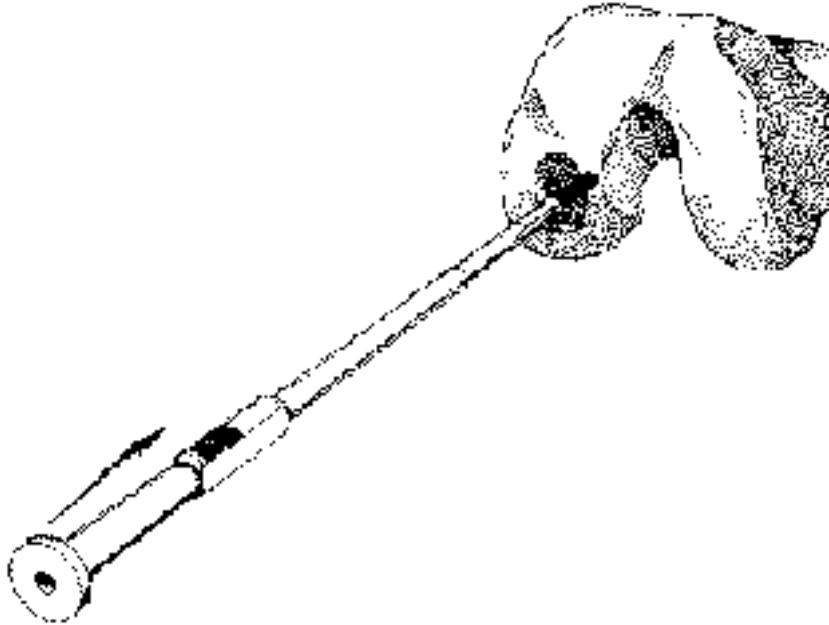


Figure 10. Insertion of graft with adjustable plunger.

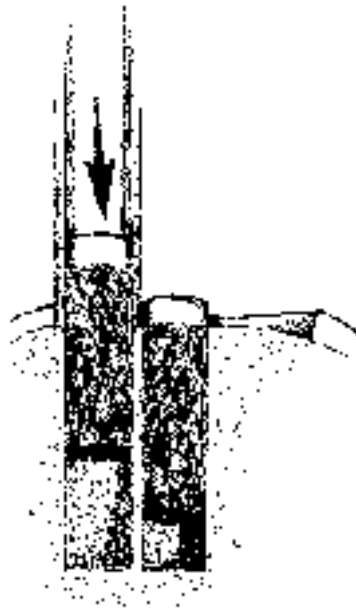


Figure 11. Care must be taken not to sit the guide tube on the previous grafts.

Deliver

1. Adjust the delivery tamp by turning the handle to initially allow the graft to sit slightly higher than the depth of the defect. This will minimize the likelihood of overpenetrating the graft.
2. **Stop Inflow**; otherwise fluid flow can push the graft out of the tube.
3. Deliver the graft under direct visualization into the recipient hole through the drill guide with the use of the delivery tamp (Figure 10).
4. The graft can be inserted deeper by turning the delivery tamp handle counter-clockwise. The graft should be flush with the original articular surface. Remove the drill guide to inspect the graft. If the graft is proud, reinsert the drill guide and gently tap the graft down with an appropriately-sized tamp.
5. Insert the subsequent grafts in a similar fashion by placing the drill guide immediately adjacent to the previously-placed grafts.

Note: Caution must be taken to keep the shoulder of the drill guide off the previously inserted grafts. This will avoid inadvertent recessing of the grafts (Figure 11).

Closure and Postoperative Treatment

When all the holes are filled and the grafts seated, put the knee through a range of motion and varus, valgus stress (Figure 12).

Close the portals and drain the joint through the superior portal.

Postoperatively, remove the drain at 24 hours. The patient is discharged and advised to remain partial weight-bearing for 2–6 weeks, or non-weight-bearing for osteochondritis dissecans. Range of motion and isometric quadriceps exercises and swimming are encouraged during this period. Barring complications, return to full activities can be accomplished in 2–4 months.

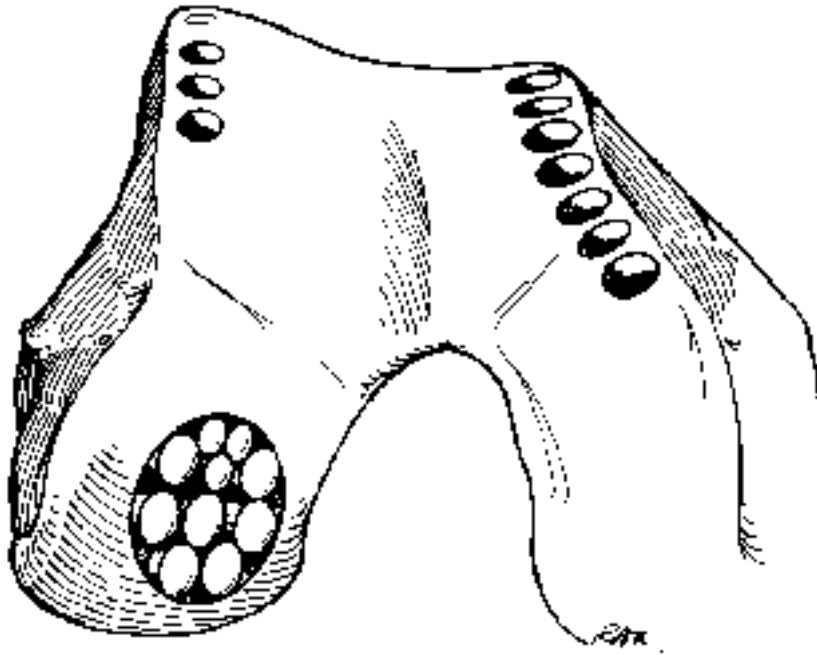


Figure 12

Bibliography

- Hangody L, Kárpáti Z. New alternative in the treatment of severe, localized cartilage damages in the knee joint. *Hungarian Journal of Traumatology and Orthopaedics*; 37:237–242, 1994.
- Hangody L, Kárpáti Z, Szerb I. Osteochondral autograft implantation in the treatment of knee chondropathy. *First prize winner poster of the 6th Congress of ESSKA*; Berlin, 1994.
- Hangody L, Sükösd L, Szigeti I, Kárpáti Z. Arthroscopic autogenous osteochondral mosaicplasty. *Hungarian Journal of Traumatology and Orthopaedics*; 39:49–54, 1996.
- Hangody L, Kárpáti Z, Szerb I. Autogenous osteochondral mosaicplasty in the treatment of osteochondritis dissecans of the talus. *First Prize winner poster of the 7th Congress of ESSKA*; Budapest, Hungary, 1996.
- Hangody L, Szigeti I, Kárpáti Z, Sükösd L. Eine neue Methode in der Behandlung von schweren, lokalen Knorpelschäden im Kniegelenk. *Osteosynthese International*; 5:316–321, 1997.
- Hangody L, Kish G, Kárpáti Z, et al. Autogenous osteochondral graft technique for replacing knee cartilage defects in dogs. *Orthopaedics International Edition*; 5:175–181, 1997.
- Hangody L, Kish G, Kárpáti Z, et al. Treatment of osteochondritis dissecans of talus: the use of the mosaicplasty technique. *Foot and Ankle International*, Vol 18 No 10 (OCT): 628–634, 1997.
- Hangody L, Kish G, Kárpáti Z, et al. Arthroscopic autogenous osteochondral mosaicplasty for the treatment of femoral condylar articular defects. *Knee Surgery Sports Traumatology Arthroscopy*; 5:262–267, 1997.
- Hangody L, Kish G, Kárpáti Z, Eberhart R. Osteochondral plugs – Autogenous osteochondral mosaicplasty for the treatment of focal chondral and osteochondral articular defects. *Operative Techniques in Orthopaedics*; Vol 7 No 4 (OCT): 312–322, 1997.
- Hangody L, Kish G, Kárpáti Z, et al. Mosaicplasty for the treatment of articular cartilage defects: application in clinical practice. *Orthopaedics*; 21:751, 1998.
- Hangody L, Kish G, Kárpáti Z. Mosaicplasty for the treatment of osteochondritis dissecans of the knee. *Journal of Sports Traumatology and Related Research*; 20:126, 1998.
- Hangody L, Kish G, Kárpáti Z. Arthroscopic autogenous osteochondral mosaicplasty – a multicentric, comparative, prospective study. *Index Traumatologie du Sport*; 5:3–7, 1998.
- Kish G, Módis L, Hangody L. Osteochondral mosaicplasty for the treatment of focal chondral and osteochondral lesions of the knee and talus in the athlete. *Clinics in Sports Medicine*; 18:45–61, 1999.
- Hangody L. The role of the mosaicplasty in the treatment of cartilage defects. In *Imhoff-Burkart: Knieinstabilitäten und Knorpelschaden*, Steinkopff Verlag; 1998.
- Hangody L. Autogenous osteochondral mosaicplasty. In *Pfeil-Siebert-Janousek-Josten: Minimal Invasive Techniques in the Orthopaedics*, Springer Verlag; 2000.
- Hangody L, Kish G. Surgical treatment of osteochondritis dissecans of the talus. In *Duparc: European Textbook on Surgical Techniques in Orthopaedics and Traumatology*, Editions Scientifiques et Medicales Elsevier; 55–630–B–10:1–5, 2000.
- Hangody L. Mosaicplasty. In *Insall J, Scott N: Surgery of the Knee*, 357–361, Churchill Livingstone; 2000.
- Hangody L. Autologous Osteochondral Mosaicplasty in the Treatment of Focal Chondral and Osteochondral Defects of the Weight-bearing Articular Surfaces. *Osteologie*; 9:63–69, 2000.
- Hangody L, Kish G, Szabó Zs, Kárpáti Z, Szerb I, Gáspár L, Módis L. Three to six year results of autologous osteochondral mosaicplasty on the talus. *Foot and Ankle International*; 22(7):552–558, 2001.
- Hangody L, Feczko P, Kemény D, Bodó G, Kish G. Autologous osteochondral mosaicplasty for the treatment of full thickness cartilage defects of the knee and ankle. *Clinical Orthopaedics*; 391:October, Suppl. 328–337, 2001.

Ordering Information

Smith & Nephew MOSAICPLASTY® Systems are available as a Complete System or Precision System, and in individual components. Both systems are suitable for open or arthroscopic surgical approaches.

The MOSAICPLASTY Complete System contains instrumentation for harvesting and placing grafts 2.7 mm, 3.5 mm, 4.5 mm, 6.5 mm, and 8.5 mm in diameter. Trephines for hard bone coring are optional and are not included. Drill bits are required, but not included. A MOSAICPLASTY Complete Sterilization Tray is included.

The MOSAICPLASTY Precision System includes instrumentation for harvesting and placing grafts 2.7 mm, 3.5 mm, and 4.5 mm in diameter. The 6.5 mm and 8.5 mm size instrumentation are offered as options for surgeons preferring larger grafts. Trephines for hard bone coring are optional and are not included. Drill bits are required, but not included. A MOSAICPLASTY Precision Sterilization Tray is included.

The MOSAICPLASTY DP Disposable System is a sterilized, single-use set comprised of a harvesting chisel, harvesting tamp, and a drill bit. Graft placement drill guides, dilators, and delivery tamps are required, but not included.

MOSAICPLASTY Systems

REF	Description
7205532	MOSAICPLASTY Complete System
7205605	MOSAICPLASTY Precision System

Graft Harvesting

Tubular Chisels (five to ten patient uses)

7207099†	2.7 mm Tubular Chisel
7207098†	3.5 mm Tubular Chisel
7207097†	4.5 mm Tubular Chisel
7205493	6.5 mm Tubular Chisel
7205494	8.5 mm Tubular Chisel

Graft Placement

Drill Guides (five to ten patient uses)

7207214†	2.7 mm Drill Guide
7207215†	3.5 mm Drill Guide
7207216†	4.5 mm Drill Guide
7205501	6.5 mm Drill Guide
7205502	8.5 mm Drill Guide

Chisel Guards

7207208†	2.7 mm Chisel Guard
7207209†	3.5 mm Chisel Guard
7207210†	4.5 mm Chisel Guard
7205499	6.5 mm Chisel Guard
7205500	8.5 mm Chisel Guard

Dilators

7205509†	2.7 mm Dilator
7205510†	3.5 mm Dilator
7205511†	4.5 mm Dilator
7205512	6.5 mm Dilator
7205513	8.5 mm Dilator

Harvesting Tamps

7207107†	2.7 mm Harvesting Tamp
7207106†	3.5 mm Harvesting Tamp
7207105†	4.5 mm Harvesting Tamp
7205495	6.5 mm Harvesting Tamp
7205496	8.5 mm Harvesting Tamp

Delivery Tamps

7207205†	2.7 mm Delivery Tamp
7207206†	3.5 mm Delivery Tamp
7207207†	4.5 mm Delivery Tamp
7205505	6.5 mm Delivery Tamp
7205506	8.5 mm Delivery Tamp

Trephines (optional—for hard bone)

7207089	2.7 mm Trephine
7207088	3.5 mm Trephine
7207087	4.5 mm Trephine
7205497	6.5 mm Trephine
7205498	8.5 mm Trephine
7207103	Trephine Adaptor for 2.7 mm, 3.5 mm, and 4.5 mm sizes
7205515	Trephine Adaptor for 6.5 mm and 8.5 mm sizes

Drill Bits (required, single use, non-sterile)

7205508	2.7 mm Drill Bit
7207212	3.5 mm Drill Bit
7207213	4.5 mm Drill Bit
7205503	6.5 mm Drill Bit
7205504	8.5 mm Drill Bit

MOSAICPLASTY DP Disposable System

7209234	3.5 mm Disposable Harvesting Set
7209235	4.5 mm Disposable Harvesting Set
7209236	6.5 mm Disposable Harvesting Set
7209237	8.5 mm Disposable Harvesting Set

† MOSAICPLASTY Precision System components

Additional Instruction

Prior to performing this technique, consult the Instructions for Use documentation provided with individual components — including indications, contraindications, warnings, cautions, and instructions.

Courtesy of Smith & Nephew, Inc.,
Endoscopy Division

Caution: U.S. Federal law restricts this device to sale by or on the order of a physician.